

2003

Lupus Anticoagulant Associated with Transient Severe Factor X Deficiency: A Report of Two Patients Presenting with Major Bleeding Complications

Aneel A. Ashrani

University of Minnesota - Twin Cities

Agnes Aysola

University of Minnesota - Twin Cities

Hani Al-Khatib MD

St. Cloud Hospital, CentraCare Health

William L. Nichols

Mayo Clinic, Rochester

Follow this and additional works at: <http://digitalcommons.centracare.com/articles>



Part of the [Hematology Commons](#), and the [Oncology Commons](#)

Recommended Citation

Ashrani, Aneel A.; Aysola, Agnes; Al-Khatib, Hani MD; and Nichols, William L., "Lupus Anticoagulant Associated with Transient Severe Factor X Deficiency: A Report of Two Patients Presenting with Major Bleeding Complications" (2003). *Articles*. 35.
<http://digitalcommons.centracare.com/articles/35>

This Article is brought to you for free and open access by the Posters and Scholarly Works at DigitalCommons@CentraCare Health. It has been accepted for inclusion in Articles by an authorized administrator of DigitalCommons@CentraCare Health. For more information, please contact schlepers@centracare.com.

Lupus anticoagulant associated with transient severe factor X deficiency: a report of two patients presenting with major bleeding complications

ANEEL A. ASHRANI,¹ AGNES AYSOLA,² HANI AL-KHATIB,³ WILLIAM L. NICHOLS⁴ AND NIGEL S. KEY¹

¹Department of Medicine, Division of Hematology, Oncology and Transplantation, and ²Department of Laboratory Medicine and Pathology of the University of Minnesota Medical School, Minneapolis, MN, ³St Cloud Hospital, St Cloud, MN, and ⁴Special Coagulation Laboratory, Division of Hematology and Internal Medicine, Mayo Clinic, Rochester, MN, USA

Received 25 July 2002; accepted for publication 4 December 2002

Summary. Acquired factor X (FX) deficiency is rare, but has been reported in diverse disease states, including systemic amyloidosis and respiratory infections. FX deficiency associated with lupus anticoagulant (LA) and a bleeding diathesis has not been previously reported. We report two patients both of whom presented with a severe bleeding diathesis after a preceding respiratory infection due to isolated FX deficiency associated with a LA. The FX deficiency and LA were transient. We conclude that patients with LA

may rarely present with severe acquired FX deficiency. This may be another mechanism whereby patients with antiphospholipid antibodies present with bleeding complications.

Keywords: lupus anticoagulant, acquired factor X deficiency, bleeding disorder/bleeding diathesis, respiratory infection.

Isolated factor X (FX) deficiency is rare and is associated with a bleeding tendency. The congenital form is inherited in an autosomal recessive manner (Peyvandi & Mannucci, 1999). Acquired FX deficiency has been frequently reported in patients with systemic amyloidosis (Choufani *et al.*, 2001), and sporadically in association with respiratory infections (Peuscher *et al.*, 1979; Currie *et al.*, 1984; Mulhare *et al.*, 1991) or other disorders, or as an idiopathic finding (Lankiewicz & Bell, 1992).

Lupus anticoagulant (LA) is an antibody that is directed against phospholipid–protein complexes. As a result, phospholipid-dependent clotting tests, such as the activated partial thromboplastin time (aPTT), are prolonged. Prothrombin and β_2 -glycoprotein 1 are the most commonly recognized target protein antigens for antiphospholipid antibodies, although other proteins such as proteins C or S have been occasionally found to be the target antigen (Arnout, 2001). Recently, antibodies directed against factor

XII (FXII) have been identified, leading to decreased FXII levels (Jones *et al.*, 2000). Most patients with LA do not bleed abnormally, except for a small subset that has a specific deficiency of factor II (LA–hypoprothrombinaemia syndrome) (Lee *et al.*, 1996). The LA–hypothrombinaemia syndrome reflects formation of prothrombin–antiprothrombin immune complexes that are cleared from circulation (Edson *et al.*, 1984; Galli & Barbui, 1999).

Here we report two patients who presented with a severe bleeding diathesis due to isolated FX deficiency associated with a LA. To our knowledge, no similar patients have been previously reported. This may be an alternative mechanism by which patients with LA may occasionally present with bleeding complications.

MATERIALS AND METHODS

All prothrombin time (PT) assays were performed using recombinant relipidated tissue factor (InnovinTM; Dade Behring, Deerfield, IL, USA). aPTT assays were performed using partial thromboplastins, including automated aPTT or Platelin L (Organon Teknika, Durham, NC, USA), or an LA-sensitive in-house aPTT reagent in which 0.075% aluminium silicate was used as an activator, and the

Correspondence: Aneel Ashrani, MB, BSc, Division of Hematology, Oncology and Transplantation, University of Minnesota Medical School, MMC 480, 420 Delaware Street SE, Minneapolis, MN 55455, USA. E-mail: ashra002@tc.umn.edu

chloroform extract of acetone-dried rabbit brain thromboplastin as the phospholipid source (Edson *et al.*, 1984). The measurement of specific clotting factor activity was performed by one-stage clotting assays (PT based for FII, FV, FVII and FX, and aPTT based for FVIII, FIX, FXI and FXII), using a mixture of the appropriate factor-deficient substrate plasma and the test plasma with 1/10, 1/20, 1/40 and 1/80 dilutions. Dilute Russell viper venom time (dRVVT) assays, including screening, mixing and confirmatory

procedures, were performed using reagents from American Diagnostica (Greenwich, CT, USA) or Sigma Diagnostics (St Louis, MO, USA). A mixing assay (1:1) was used to screen for neutralizing antibodies to FX, monitored by assay of FX coagulation activity (FX:C), both immediately after mixing and following 1 or 2 h incubation at 37°C. Additionally, we screened for non-neutralizing antibodies to FX, using FX-crossed immunoelectrophoresis (Edson *et al.*, 1984).

Table I.
(A) Summary of selected laboratory test results.

Parameter	Patient 1	Patient 2	Reference range
Platelets ($\times 10^9/l$)	223	207	150–450
APTT (s)	63.0	76.3	21–33
PT (s)	110.7	45.5	8.4–12
TT (s)	17	18.8	18–25
Factor II:C	123%	97%	70–130%
Factor V:C	68%	103%	70–130%
Factor VII:C	85%	72%	70–130%
Factor VIII:C	408%	260%	75–135%
Factor IX:C	Not done	144%	75–135%
Factor X:C	< 3%	3%	70–130%
Factor XI:C	95%	Not done	65–150%
Factor XII:C	55%	Not done	65–200%
ESR (mm/h)	68	76	0–30
Fibrinogen (g/l)	4.64	5.96	1.7–3.7
D-dimer (ng/ml)	250	500–1000	0–300

PT, prothrombin time; aPTT, activated partial thromboplastin time; TT, thrombin time; ESR, erythrocyte sedimentation rate.

(B) Summary of laboratory data to identify lupus anticoagulant

Laboratory test	Patient 1			Patient 2		
	PNP	Patient 1	Patient:PNP (1:1)	PNP	Patient 2	Patient:PNP (1:1)
aPTT using aluminium silicate (s)	30.2	78.8	42.7	28.1	84.8	35.9
aPTT using Organon Teknika (s)	31.3	60.4	42.3			
Platelet neutralization test (aPTT based, using aluminium silicate)						
Plasma (s)	30.5	80.8		28.8	81.9	
+ Buffer control (s)	31.5	46.6		30.7	63.8	
+ Freeze-thawed platelets (s)	28.6	42.8		31.3	64.7	
StacLOT LA (Diagnostica Stago, Parsippany, NJ, USA)						
Baseline aPTT (s)		125				
Hexagonal-phase aPTT (s)		63				
DRVVT						
Screen (s); patient/PNP ratio (normal ratio < 1.2)	35.1	> 150; > 4.27				
1:4 mix screen (s); patient/PNP ratio (normal ratio < 1.2)	35.5	117.3; 3.34				
Confirm (s); normalized ratio (normal ratio < 1.2)	29.7	53.5; 2.37				
Prothrombin time (s)	9.7	110.7	30.2			

DRVVT, dilute Russell viper venom time; PNP, pooled normal plasma.

CASE REPORT

Patient 1. A 62-year-old man presented to his local hospital in March 2001 with a 2-d history of progressive swelling and bruising in his right knee and calf, and haematuria. He had a 3-month history of a dry cough. There was no personal or family history of bleeding diathesis. Laboratory studies showed: haemoglobin 10.7 g/dl, PT > 100 s and aPTT 79 s. The prolonged PT and PTT did not correct on 1:1 mixing with normal plasma. Chest radiograph revealed a right middle lobe infiltrate. His condition worsened, with increasing right leg swelling, development of numbness and weakness of the right foot, in conjunction with a declining haemoglobin (nadir 5.2 g/dl). He was then transferred to our centre for further management.

On examination, the patient had large ecchymotic lesions in both axillary folds, over the right infra-axillary chest wall and the right calf. His right thigh was swollen and the right calf was tense. He had no sensation below his right ankle and was unable to dorsi- or plantar-flex his right ankle or toes.

Pertinent laboratory results are summarized in Table IA. Additional laboratory tests were consistent with the presence of a potent coagulation inhibitor that fulfilled criteria for a strong LA (Table IB), with associated FX deficiency. A mixing study of the prolonged PT demonstrated definite inhibition. The patient's plasma inhibited the assay systems for coagulation factors II, V, VII and VIII but, using four serial dilutions, the activity progressively increased into the normal range. However, no FX (< 3%) activity could be demonstrated at any dilution. The FX inhibitor screening assay was negative, as was the Bethesda assay for a FX inhibitor [< 1 Bethesda Unit (BU)]. Crossed immuno-electrophoresis (CIEP) revealed no evidence of FX-anti-FX immune complexes.

An emergency four-compartment fasciotomy was performed for a diagnosis of calf compartment syndrome. Because the patient refused blood products (Jehovah's Witness), he was administered recombinant FVIIa (rFVIIa; NovoSevenTM) 120 µg/kg intravenously prior to surgery, followed by 90 µg/kg every 2 h for 12 h. Additionally, he

received prednisone 100 mg daily and the macrolide antibiotic azithromycin.

Subsequently, FX activity recovered to normal levels over the course of about 1 week (Fig 1). No additional bleeding occurred. Evaluations for monoclonal paraproteinaemia and lung cancer were negative, as were bacteriological studies of blood and sputum. An LA screen at 8 weeks revealed that the inhibitor was no longer present. Anticardiolipin and beta-2-glycoprotein antibodies were negative at this time. The patient had persistent foot drop and sensory loss in his right foot on later follow-up.

Patient 2. A 59-year-old man presented in October 1997 with a 4-d history of headache, fever, chills and mild epistaxis, and a 1-d history of gross haematuria and back pain. Additionally, he complained of dry cough, anorexia and fatigue. There was no personal or family history of excessive bleeding. On physical examination, his abdomen was distended and tender. Pertinent laboratory tests are summarized in Table IA. He was administered vitamin K and fresh-frozen plasma with only minor correction of PT and aPTT. Over the ensuing 2 d, his haemoglobin declined to 7.7 g/dl. Computerized tomography (CT) of the chest and abdomen revealed mediastinal adenopathy, bilateral pleural effusion, large retroperitoneal bleed, right kidney obstruction, and a filling defect (presumably haematoma) in the left renal pelvis and the urinary bladder. Serum protein electrophoresis did not demonstrate any monoclonal paraproteins. The bacteriological studies of blood and urine were negative.

aPTT mixing studies demonstrated an inhibitor, with a positive platelet neutralization procedure, indicating the presence of a moderate LA (Table IB). FX inhibitor screening assay demonstrated no immediate or progressive inhibition of FX activity in normal plasma. On the FX antigen CIEP, there was no evidence of FX-anti-FX immune complexes.

The patient was treated with packed red blood cell transfusions, fresh-frozen plasma, vitamin K and ceftriaxone with good clinical result. At dismissal on d 8, his PT was 16 s and aPTT 37 s. Cystoscopy revealed no evidence of tumour, and lymph node biopsies from the mediastinum were consistent with a reactive process. He made an uneventful recovery.

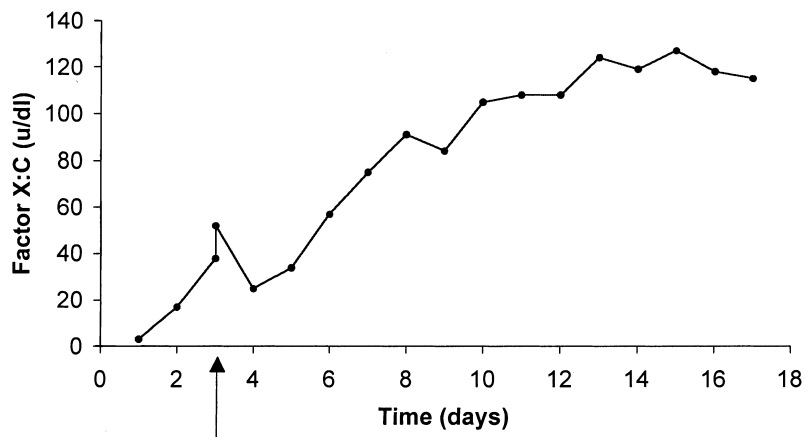


Fig 1. Factor X activity over time for Patient 1. The arrow represents the day of administration of rFVIIa. The apparent transient rise in FX:C at that time probably reflects shortening of the PT due to high concentrations of rFVIIa in the sample.

DISCUSSION

In this report, we present the clinical data of two patients with a transient, postinfectious, isolated, acquired FX deficiency, associated with LA, which in both patients presented with a serious bleeding diathesis. In patient 1, rFVIIa was effective in controlling bleeding during fasciotomy, similar to that found by Boggio and Green (2001) in amyloid-associated FX deficiency.

We could not demonstrate free, circulating FX neutralizing antibodies, either immediately after mixing or following a 1–2 h incubation at 37°C, in either patient. Furthermore, we were unable to establish the presence of circulating non-neutralizing FX–anti-FX immune complexes. We, therefore, speculate that all of the anti-FX antibody was utilized *in vivo*, with accelerated immune-mediated clearance of FX. This syndrome may thus be akin to LA–hypoprothrombinaemia syndrome, which is due to the formation of a non-neutralizing antiprothrombin antibody, and can also be a transient postinfectious phenomenon (Lee *et al.*, 1996). Transient FX deficiency may be another mechanism whereby patients with antiphospholipid antibodies develop bleeding complications. Additionally, this report highlights the varied spectrum of antibody specificity or crossreactivity of lupus anticoagulant.

REFERENCES

- Arnout, J. (2001) Antiphospholipid syndrome: diagnostic aspects of lupus anticoagulants. *Thrombosis Haemostasis*, **86**, 83–91.
- Boggio, L. & Green, D. (2001) Recombinant human factor VIIa in the management of amyloid-associated factor X deficiency. *British Journal of Haematology*, **112**, 1074–1075.
- Choufani, E.B., Sanchowawala, V., Ernst, T., Quillen, K., Skinner, M., Wright, D.G. & Seldin, D.C. (2001) Acquired factor X deficiency in patients with amyloid light-chain amyloidosis: incidence, bleeding manifestations, and response to high-dose chemotherapy. *Blood*, **97**, 1885–1887.
- Currie, M.S., Stein, A.M., Rustagi, P.K., Behrens, A.N. & Logue, G.L. (1984) Transient acquired factor X deficiency associated with pneumonia. *New York State Journal of Medicine*, **84**, 572–573.
- Edson, J.R., Vogt, J.M. & Hasegawa, D.K. (1984) Abnormal prothrombin crossed-immunoelectrophoresis in patients with lupus inhibitors. *Blood*, **64**, 807–816.
- Galli, M. & Barbui, T. (1999) Antiprothrombin antibodies: detection and clinical significance in the antiphospholipid syndrome. *Blood*, **93**, 2149–2157.
- Jones, D.W., Gallimore, M.J., MacKie, I.J., Harris, S.L. & Winter, M. (2000) Reduced factor XII levels in patients with the antiphospholipid syndrome are associated with antibodies to factor XII. *British Journal of Haematology*, **110**, 721–726.
- Lankiewicz, M.W. & Bell, W.R. (1992) A unique circulating inhibitor with specificity for coagulation factor X. *American Journal of Medicine*, **93**, 343–346.
- Lee, M.T., Nardi, M.A., Hadzi-Nesic, J. & Karparkin, M. (1996) Transient hemorrhagic diathesis associated with an inhibitor of prothrombin with lupus anticoagulant in a 1 1/2-year-old girl: report of a case and review of the literature. *American Journal of Hematology*, **51**, 307–314.
- Mulhare, P.E., Tracy, P.B., Golden, E.A., Branda, R.F. & Bovill, E.G. (1991) A case of acquired factor X deficiency with *in vivo* and *in vitro* evidence of inhibitor activity directed against factor X. *American Journal of Clinical Pathology*, **96**, 196–200.
- Peuscher, F.W., van Aken, W.G., van Mourik, J.A., Swaak, A.J., Sie, L.H. & Statius van Eps, L.W. (1979) Acquired, transient factor X (Stuart factor) deficiency in patient with mycoplasma pneumoniae infection. *Scandinavian Journal of Haematology*, **23**, 257–264.
- Peyvandi, F. & Mannucci, P.M. (1999) Rare coagulation disorders. *Thrombosis and Haemostasis*, **82**, 1207–1214.